

Course # 118

**SECO2026**  
THE EDUCATION DESTINATION™

**AMD:**  
**How to Improve Outcomes  
and Prevent Blindness**

Damon Dierker, OD

Please Silence All Mobile Devices.  
[attendseco.com](http://attendseco.com)

1

**SECO2026**  
THE EDUCATION DESTINATION™

**Damon Dierker, OD**

Disclosure statements:  
*AbbVie/Allergan: Consulting Fees | Alcon: Advisory Board, Consulting Fees, Speaker's Bureau | Apellis: Speaker's Bureau | Astellas: Consulting Fees | Azura Ophthalmics: Advisory Board | Balance Ophthalmics: Advisory Board, Consulting Fees | Bausch + Lomb: Advisory Board, Consulting Fees, Speaker's Bureau | BioTissue: Advisory Board, Consulting Fees, Researcher, Speaker's Bureau | Bruder: Advisory Board | C. Light Technologies: Advisory Board | Derma Cautery: Advisory Board | Dome: Speaker's Bureau | LENZ Therapeutics: Speaker's Bureau | Nordic Pharma: Advisory Board, Consulting Fees | Novoxel: Consulting Fees | NuSight Medical: Consulting Fees | Ocubio: Consulting Fees | ScienceBased Health: Advisory Board, Consulting Fees, Speaker's Bureau | Sight Sciences: Advisory Board, Consulting Fees, Researcher, Speaker's Bureau | Sun Pharma: Advisory Board, Speaker's Bureau | Tarsus: Advisory Board, Consulting Fees, Researcher, Speaker's Bureau | Thea Pharma: Advisory Board, Consulting Fees | Viatrix: Advisory Board, Consulting Fees, Researcher, Speaker's Bureau | Visionix: Consulting Fees | ZEISS: Advisory Board*

All relevant relationships have been mitigated.

2

**AMD: How to Improve Outcomes  
and Prevent Blindness**


Damon Dierker, OD, FAAO

3


**Disclosures - Damon Dierker, OD, FAAO**

- Abbvie - C
- Alcon - A/C/S
- Apellis - S
- Astellas - C
- Azura - A
- Balance Ophthalmics - A/C
- Bausch & Lomb - A/C/S
- Bio-Tissue - A/C/R/S
- Bruder - A
- Carl Zeiss Meditec - A
- C. Light Technologies - A
- Derma Cautery - A
- Dome - S
- LENZ Therapeutics - S
- Nordic Pharma - A/C
- Novoxel - C
- NuSight Medical - C
- Ocubio - C
- ScienceBased Health - A/C/S
- Sight Sciences - A/C/R/S
- Sun Pharma - A/S
- Tarsus - A/C/R/S
- Thea Pharmaceuticals - A/C
- Viatrix - A/C/R/S
- Visionix - C

A - Advisory Board  
C - Consultant  
R - Research  
S - Speaker Bureau

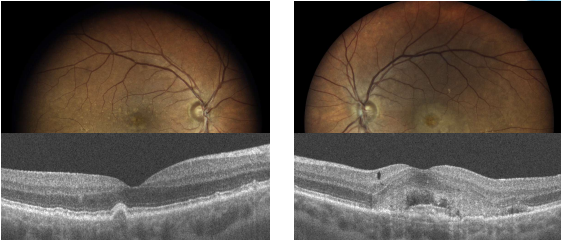


All relevant financial relationships have been mitigated. The content of this CPE. Accredited CE activity was planned and prepared independently by Damon Dierker, OD, FAAO without input from members of an ineligible company.



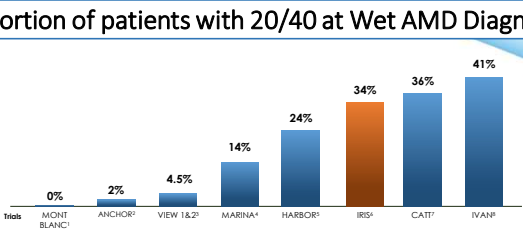
4

**New Patient – Cataract Consult**



5

**Proportion of patients with 20/40 at Wet AMD Diagnosis**



Study	Proportion of patients with 20/40 at Wet AMD Diagnosis
MONTE BLANC <sup>1</sup>	0%
ANCHOR <sup>2</sup>	2%
VIEW 1 & 2 <sup>3</sup>	4.5%
MARINA <sup>4</sup>	14%
HARBOR <sup>5</sup>	24%
IBES <sup>6</sup>	34%
CATT <sup>7</sup>	36%
IVAN <sup>8</sup>	41%

Regardless of clinical trials or the real world, the majority of patients start with poor visual acuity (20/63-20/125).

6

## Lecture Goals - AMD

- Review best practices in diagnosis and classification
- Understand modern imaging approaches to stratify risk progression
- Implement stage-specific management strategies
- Evaluate emerging and approved therapies responsibly



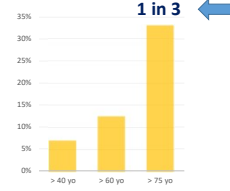

7

## AMD affects ~20 million people in U.S.

**Prevalence of Major Eye Disease in the U.S.**  
(Adults >40 years)

Disease	Prevalence (Millions of People)
Glaucoma	4.2
Diabetic Retinopathy	8.0-9.6
Age-Related Macular Degeneration (AMD)	19.8

**AMD Prevalence by Age in U.S.**

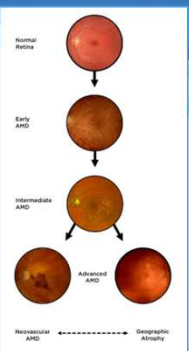


Gupta P, et al. Invest Ophthalmol Vis Sci. 2016 May;57(6):2577-2585.  
Rein DB, Wittenborn JS, et al. JAMA Ophthalmol. 2022 Dec 1;140(12):1202-1208.  
<https://www.cdc.gov/vision-health-data/prevalence-estimates/diag-prevalence.html> accessed 12/27/25.  
Ehrlich JR, Burke-Conte Z, Wittenborn JS, et al. JAMA Ophthalmol. 2024;142(11):1046-1053.

8

## AMD is Not One Disease

- AMD represents a **spectrum of overlapping biologic pathways**
- Multiple mechanisms involved:
  - Oxidative stress
  - Lipid dysregulation
  - Chronic inflammation
- Final common outcomes include neovascular AMD (CNV) and geographic atrophy
- Patients with similar fundus appearance may have **very different progression risks**



Cheung CMG, et al. Lancet. 2017;390(10109):1499-1513.  
<https://www.asegpaifrcntr.co.uk/about-us/identifying-ga>. Accessed 12/28/25.

9


## AMD Risk Factors

**Established**

- Age
- Genetics
- Gender
- Family history
- Smoking
- Nutrition

**Putative**

- Light exposure
- Obesity
- Cardiovascular disease
- Low macular pigment levels
- Diabetes



**Risk factors determine speed of disease progression, likelihood of GA vs CNV phenotype, and response to lifestyle and therapeutic interventions**

Seddon JM, et al. Arch Ophthalmol. 2003;121(6):785-792.  
Klein R, et al. Arch Ophthalmol. 2007;125(5):671-679.  
Seddon JM, et al. JAMA. 1994;272(18):1413-1420.

10

## AMD Pathophysiology

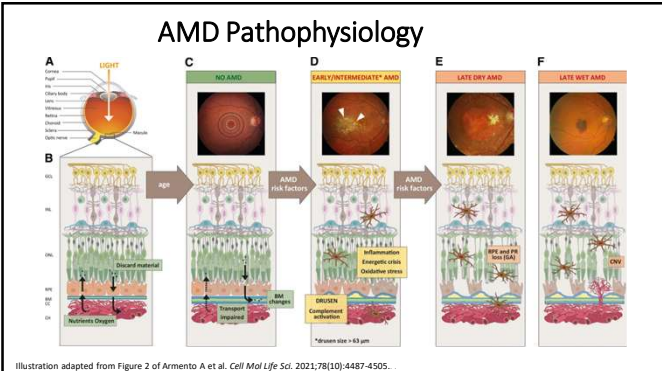
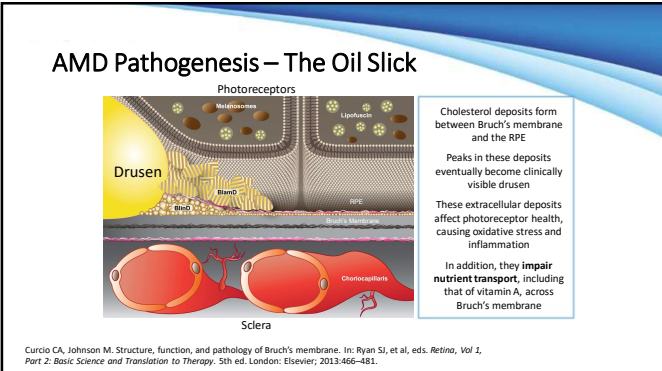


Illustration adapted from Figure 2 of Armento A et al. Cell Mol Life Sci. 2021;78(10):4487-4505.

11

## AMD Pathogenesis – The Oil Slick



**Photoreceptors**

**Drusen**

**Cholesterol**

**Sclera**

**Choriocapillaris**

**Bruch's Membrane**

**RPE**

**Photoreceptors**

**Cholesterol deposits form between Bruch's membrane and the RPE**

**Peaks in these deposits eventually become clinically visible drusen**

**These extracellular deposits affect photoreceptor health, causing oxidative stress and inflammation**

**In addition, they impair nutrient transport, including that of vitamin A, across Bruch's membrane**

Curcio CA, Johnson M. Structure, function, and pathology of Bruch's membrane. In: Ryan SJ, et al, eds. Retino, Vol 2, Part 2. Basic Science and Translation to Therapy. 5th ed. London: Elsevier; 2013:466-481.

12


**JAMA Ophthalmology | Original Investigation**  
**Prevalence of Undiagnosed Age-Related Macular Degeneration in Primary Eye Care**

David C. Neely, MD, Kevin J. Bray, MD, Carrie E. Hsing, MPH, Mark E. Clark, BS, Gerald McVinn Jr, PhD, Cynthia Owensley, PhD

- Published in *JAMA Ophthalmology* in 2017
- 1288 eyes (644 adults ≥ age 60)
- Most recent comprehensive dilated examination did not indicate a diagnosis of AMD
- Color photos were reviewed by masked, trained graders who determined the presence or absence of AMD findings

**25% of “normal” patients had findings c/w AMD**  
 Almost 1/3rd of missed AMD eyes had large drusen

Neely DC, et al. *JAMA Ophthalmol.* 2017;135(6):570-5.



13

### Why Classification Matters

- Provides standardized clinical language
- Anchors management thresholds
- Aligns patient care with clinical trials
- Supports documentation, billing, and referrals

TABLE. BECKMAN CLASSIFICATION OF AMD	
Disease Stage	Definition
No apparent aging changes	- No drusen - No AMD pigmentary abnormalities*
Normal aging changes	- Only small drusen ≤ 63 μm - No AMD pigmentary abnormalities*
Early AMD	- Medium drusen > 63 μm and ≤ 125 μm - No AMD pigmentary abnormalities*
Intermediate AMD	Large drusen > 125 μm and/or any AMD pigmentary abnormalities*
Late AMD	Neovascular AMD and/or GA

\*AMD pigmentary abnormalities: any definite druse or hypopigmentary abnormalities associated with medium or large drusen but not associated with lesion disease entities.

Ferris FL III, et al. *Ophthalmology.* 2013;120(4):844-851.  
<https://retinatoday.com/article/2022-may-june/retinking-our-amd-nomenclature>. Accessed 12/28/25.

14

### The Beckman Committee Classifies AMD Into 4 Stages

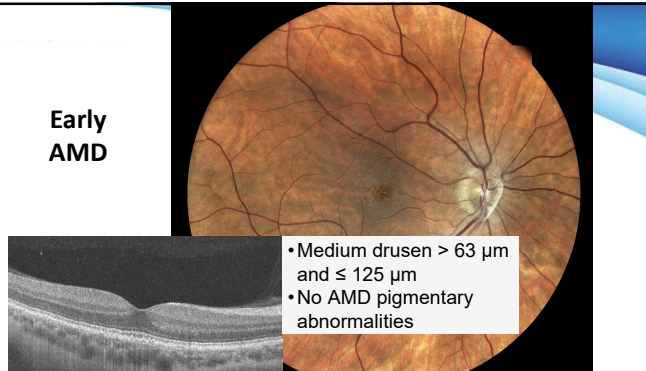
Progression ↓

- No AMD**
  - None or few drupelets (small drusen ≤ 63 μm)
  - No AMD pigmentary abnormalities
- Early AMD**
  - Medium drusen > 63 μm and ≤ 125 μm
  - No AMD pigmentary abnormalities
- Intermediate AMD**
  - Large drusen > 125 μm and/or
  - Any AMD pigmentary abnormalities
- Advanced AMD** (2 forms)
  - Geographic Atrophy (GA)
  - Neovascular AMD (CNV)

Ferris FL, et al. *Ophthalmology.* 2013;120(4):844-851.

15

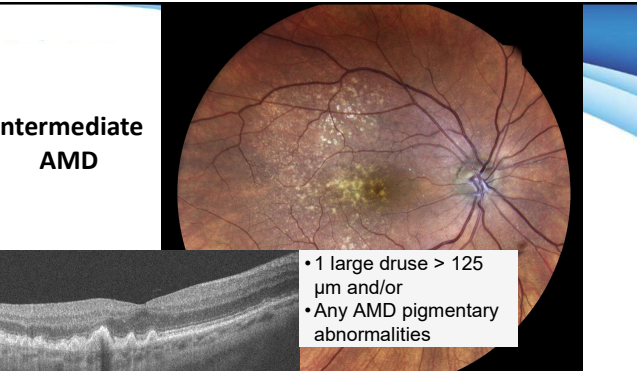
### Early AMD



- Medium drusen > 63 μm and ≤ 125 μm
- No AMD pigmentary abnormalities

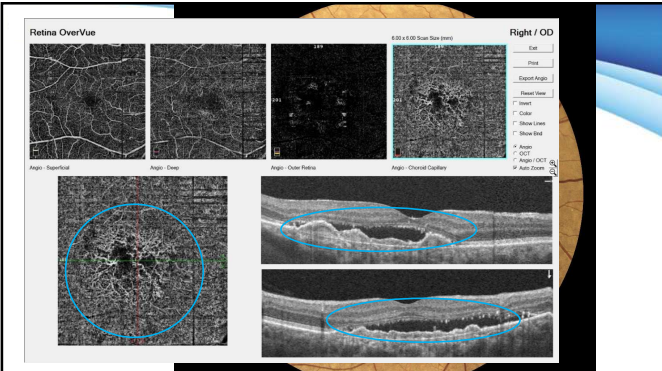
16

### Intermediate AMD



- 1 large druse > 125 μm and/or
- Any AMD pigmentary abnormalities

17



Retina OverVue

Right / OD

600 x 600 Scan Size (mm)

Export Angle

Reset View

Image

Color

Show Lines

Show Grid

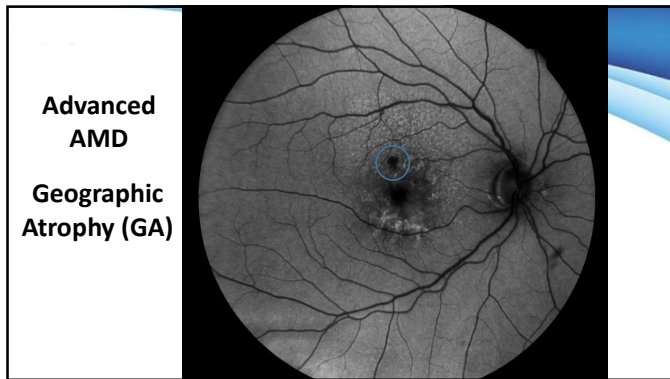
Auto

OCCT

Angle / OCCT

Auto Zoom

18



19

### AREDS Simplified Severity Scale

- Clinic-friendly tool to estimate 5-year risk of progression to late AMD
- Designed for patient counseling, not diagnosis
- Based on fundus findings for each eye

**Risk Factors Scored**

- Large drusen → 1 point per eye
- Pigment abnormalities → 1 point per eye

**Scoring**

- Total score: 0-4
- Higher score = higher 5-year risk of late AMD

Ferris, FL III, et al. Arch Ophthalmol. 2005;123(11):1570-1574.

20

### AREDS Simple Scale

Right Eye

- Large Drusen: No=0, Yes=1
- Pigment Changes: No=0, Yes=1

Left Eye

- Large Drusen: No=0, Yes=1
- Pigment Changes: No=0, Yes=1

Large Drusen and Pigment Changes → Patient Severity Score = 4 Risk Factors

No. of Risk Factors	Event Rate (%)
0	0.5%
1	3.0%
2	12.0%
3	25.0%
4	50.0%

Ferris, FL III, et al. Arch Ophthalmol. 2005;123(11):1570-1574.

21

### Simple Scale Update - 2024

**Limitations of Original Model**

- Based on color fundus photography
- Didn't account for:
  - Advanced OCT biomarkers
  - Different drusen phenotypes
- Some patients progressed faster than predicted

**Why do some patients with the same AREDS simple score have very different outcomes?**

**Answer: Not all drusen carry the same risk**

Agron E, et al. Ophthalmology. 2024;131:1164-1174.

22

### Reticular Pseudodrusen (RPD) : The Missing Risk Factor

**What are RPD?**

- Subretinal drusenoid deposits
- Located above the RPE
- High-risk AMD phenotype independent of drusen size
- Best detected with:
  - OCT
  - Near-infrared reflectance
  - Fundus autofluorescence

**Why They Matter**

- Faster progression to late AMD
- Higher risk of geographic atrophy
- Impaired dark adaptation

Agron E, et al. Ophthalmology. 2024;131:1164-1174.

23

### Updated AREDS Simplified Scale

**What Changed**

- Same 0-4 scoring system
- Risk estimates now stratified by:
  - RPD absent
  - RPD present

**Outcome Definition Updated**

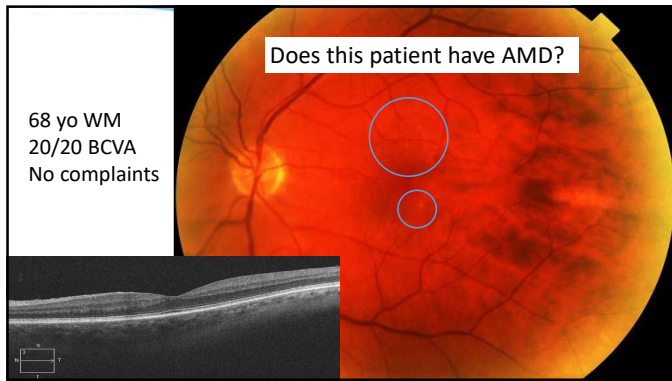
- Late AMD now includes:
  - Neovascular AMD
  - Any geographic atrophy (central or non-central)

**• Same scale – better risk prediction**

RPD Status	Score	Event Rate (%)
No RPD	0	0.5%
	1	4.0%
	2	12.0%
	3	27.0%
Yes RPD	0	3.0%
	1	8.0%
	2	29.0%
	3	72.0%

Agron E, et al. Ophthalmology. 2024;131:1164-1174.

24



25

### 2014-2019: Measuring Dark Adaptation

CPT 92284

- Automated dark adaptometer
- Simple, objective tool to measure dark adaptation as earliest functional correlate of AMD
- Two clinical protocols
  - Rapid test (<6.5 minutes)
  - Extended test

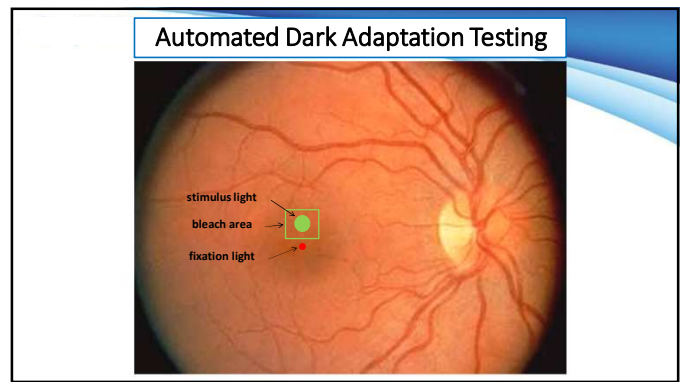
26

### 2020: Measuring Dark Adaptation

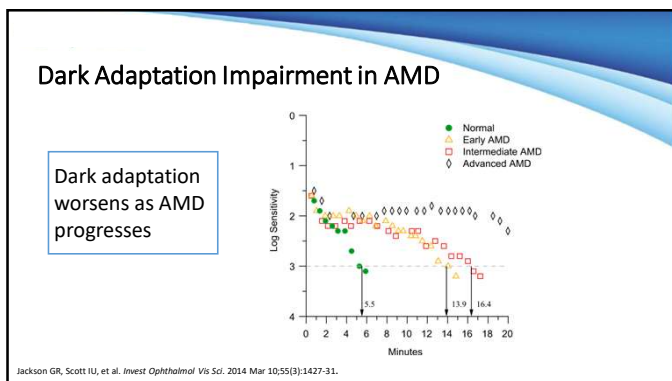
CPT 92284

- Automated dark adaptometer
- Simple, objective tool to measure dark adaptation as earliest functional correlate of AMD
- Two clinical protocols
  - Rapid test (<6.5 minutes)
  - Extended test

27



28



29

### Dark Adaptometry Diagnostic Study

Rod Intercept <6.5 = normal  
Rod Intercept >6.5 = AMD

**High Sensitivity:**

- Correctly identified 90.6% of confirmed AMD cases

**High Specificity:**

- Correctly identified 90.5% of confirmed normal cases


**High Accuracy:**

- 90.6% overall accuracy

Jackson GR, Scott IU, et al. Invest Ophthalmol Vis Sci. 2014 Mar 10;55(3):1427-31.

30

### Early Detection with Dark Adaptometry



Impaired dark adaptation identifies subclinical AMD at least **three years before** it can be seen with imaging or clinical exam.

**Prospective Study of Subclinical AMD**  
 Sample consisted of 325 adults without clinically detectable AMD. At baseline, 24% of the subjects exhibited impaired dark adaptation. AMD status determined at 3-year follow-up visit.

Oswley et al. Ophthalmology. 2016;123(2):344-351.

31


## Questions?

damon.dierker@esi-in.com

32


### Risk Reduction in Early AMD: What Actually Matters

- Stop Smoking**  
Most impactful modifiable risk factor
- Eat better**  
Diet patterns matter more than a single nutrients
- Move more**  
Physical activity supports retinal and vascular health
- Control blood pressure and metabolism**  
Systemic vascular disease increases retinal risk
- Optimize macular pigment**  
Dietary intake first, consider targeted supplementation
- Limit ongoing UV / blue-light exposure**  
Reasonable protection reduces retinal stress
- Monitor intelligently**  
Risk-based follow-up and prompt evaluation of new symptoms



33

## DON'T SMOKE EVER AGAIN!



**Smoking and AMD**

- Depletes serum antioxidants
- Decreases macular pigment density
- Increases risk of progression to advanced AMD

**Discuss strategies for quitting, consider referral**

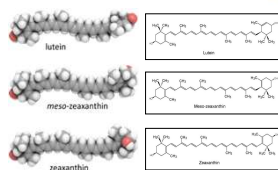
*Helping these patients to stop smoking is the most powerful thing we can do to reduce risk of vision loss*

Seddon JM, et al. JAMA. 1994;272(18):1413-1420.  
 Klein R, et al. Arch Ophthalmol. 2007;125(5):671-679.  
 Caban-Martinez AL, Davila EP, et al. Prev Chronic Dis. 2011 Nov;8(5):A147.

34

### Macular Carotenoids and AMD

- Lutein, zeaxanthin, meso-zeaxanthin
- Dietary carotenoids and AMD
  - Green leafy vegetables (spinach, kale)
  - AREDS showed benefit w/ ↑ dietary intake
    - ↓ Risk of wet AMD and geographic atrophy
    - Drusen progression slowed
- Supplemental carotenoids and early AMD
  - Improve visual function
  - Improve macular pigment density
  - Reduce risk of AMD progression?




AREDS Report No. 22. Arch Ophthalmol. 2007;125(9):1225-1232.  
 Akuflo KO et al. Invest Ophthalmol Vis Sci. 2017;58:5347-5360.

35

### Dietary Omega-3 Fatty Acids (Fish Intake)

- Observational cohort studies consistently associate **dietary omega-3 intake** with lower AMD risk
- **Blue Mountains Eye Study (BMES):**
  - ≥1 serving of fish per week associated with **reduced incidence of early AMD and progression**
- **Women's Health Study:**
  - ≥1 serving of fish per week associated with **lower risk of AMD development**
- **AREDS observational analyses:**
  - Participant with the **highest dietary omega-3 intake** had lower risk of AMD incidence and progression
- Likely reflects anti-inflammatory, vascular, and metabolic benefit



Chua B, et al. Arch Ophthalmol. 2006;124:981-986.  
 Christen, et al. Arch Ophthalmol. 2011;129(7):921-929.  
 Seddon JM, et al. Ophthalmology. 2013;120(8):1619-31.

36


### Omega-3 Supplements and AMD

**What the Best Evidence Shows**

- **AREDS2:** DHA/EPA supplementation showed **no reduction** in progression to advanced AMD
- **Long-term AREDS2 follow-up** confirms **no benefit** for late AMD
- **Cochrane review:** RCTs **do not support omega-3 supplements** for AMD prevention
- Some biomarker studies suggest lower CNV risk with higher DHA levels (observational only)

**Clinical Takeaway**

- Omega-3 supplements should **not** be recommended solely for AMD prevention or treatment



Age-Related Eye Disease Study 2 Research Group. JAMA. 2013;309(19):2005-2015.  
Chew EY, et al. JAMA Ophthalmol. 2022;140(7):692-698.  
Lawrence JG, Evans JR. Cochrane Database Syst Rev. 2015;(4):CD010015

37

### UV and Blue-Light Exposure: Practical Counseling

**What we know**

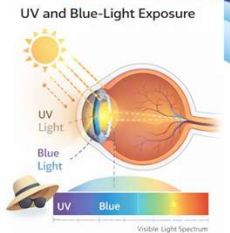
- UV and blue light contribute to retinal stress
- RPE and photoreceptors are vulnerable to long-term exposure

**What we cannot change**

- Past cumulative light exposure cannot be reversed

**What we can do**

- Limit ongoing UV exposure, especially outdoors
- Blue-light filtering lenses may improve comfort/glare
- Avoid fear-based messaging, particularly around screens



Sliney DH. Prog Retin Eye Res. 2016;52:1-26.  
Algyere PV, et al. Acta Ophthalmol Scand. 2006;84(1):4-15.  
American Academy of Ophthalmology. Blue Light & Eye Health. 2023.

38

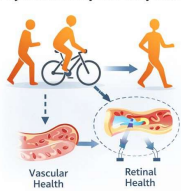
### Move More: Physical Activity and Early AMD

**What the evidence suggests**

- Regular physical activity associated with:
  - Lower risk of AMD progression
  - Reduced incidence of advanced AMD

**Clinical counseling**

- Encourage regular, moderate physical activity
- Emphasize consistency over intensity
- Frame exercise as part of overall retinal risk reduction



Knudtson MD, et al. Arch Ophthalmol. 2006;124(2):249-254.  
McGuinness MB, et al. Surv Ophthalmol. 2017;62(3):296-309.  
Chakravarthy U, et al. Prog Retin Eye Res. 2010;29(6):593-611.

39

### Systemic Health and AMD Risk Reduction

**Why physical activity matters**

- Improves vascular endothelial function
- Enhances mitochondrial efficiency
- Reduces systemic inflammatory burden

**Why metabolic control matters**

- Hypertension associated with:
  - Choroidal vascular compromise
  - Higher risk of advanced AMD
- Obesity and insulin resistance accelerate retinal aging


**AMD is not an isolated ocular disease – it reflects systemic vascular and metabolic health**

Klein R, et al. Arch Ophthalmol. 2007;125(5):671-679.  
McGuinness MB, et al. Prog Retin Eye Res. 2017;57:1-27.  
Chakravarthy U, et al. Nat Rev Dis Primers. 2020;6:31.

40

### Metformin Use and AMD Risk: Observational Signals

- Long-term metformin use has been associated with:
  - Lower incidence of AMD
  - Reduced progression to advanced disease
- Proposed mechanisms
  - Improved insulin sensitivity
  - Reduced oxidative stress
  - AMPK activation and mitochondrial support
- Findings are **observational** and subject to confounding
- Metformin should **not** be initiated for AMD prevention alone




Eyes On Eye Care – Glance. 2025 Oct 21. Lower AMD risk tied to long-term metformin use.  
Hong A T, Liu Y, et al. Ophthalmol Retina. 2025 Aug 11;52468-6530(25)00354-9.

41

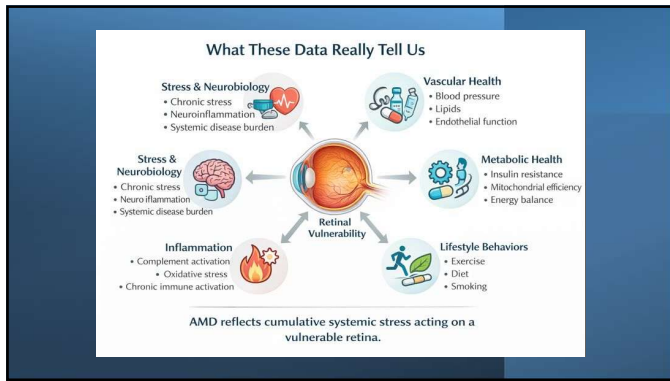
### Antidepressants Use and AMD Risk: Early Observations

- Observational studies suggest **some antidepressants may be associated with lower AMD risk**
- Proposed mechanisms:
  - Anti-inflammatory effects
  - Modulation of oxidative stress pathways
  - Reduced systemic stress burden
- Significant confounding likely:
  - Health-seeking behavior
  - Comorbidity differences
- These findings should **not** alter prescribing decisions



Eyes On Eye Care – Glance. 2025 Nov 10. Antidepressant use may lower AMD risk.  
Mahmoudzadeh R, et al. Am J Ophthalmol. 2025; 50002-9394(25)00466-0.

42



43

### Early AMD: What I Actually Do in Clinic

**Typical findings**

- Small to medium-sized drusen
- No significant pigmentary changes
- Preserved visual function

**Monitoring**

- In-office follow-up: **every 12 months**

**Patient self-monitoring**

- Amsler grid

**Imaging**

- Color fundus photography
  - Baseline documentation
- OCT
  - Actively screen for reticular pseudodrusen (RPD) and other OCT biomarkers\*
- OCTA
  - Consider selectively if OCT or symptoms raise concern

**Nutritional strategy**

- Diet rich in leafy greens and omega-3s
- Triple carotenoid supplement

**Counseling focus**

- Smoking cessation
- Cardiovascular risk optimization
- UV/blue-light protection
- Set expectations: low short-term risk, long-term vigilance

Ferris FL III, et al. Ophthalmology. 2013;120(4):844-851. Stringham JM, et al. Prog Retin Eye Res. 2019;68:1-23. American Academy of Ophthalmology. PPP AMD. 2023.

44

## Questions?

damon.dierker@esi-in.com

45

### Why Intermediate AMD is Not All The Same

**Common perception**

- Intermediate AMD often treated as a single-risk category
- Management decisions frequently based on fundus appearance alone

**Traditional framework**

- AREDS Simple Scale remains a useful starting point

**What we now recognize**

- Patients with similar fundus findings can have markedly different progression trajectories

**Second hour focus:**

- Shift Use of advanced tools **selectively**, not routinely
- Match the **intensity of care to the biologic risk of the retina – not the diagnosis alone**

**Intermediate AMD represents a spectrum of disease, not a uniform diagnosis**

Ferris FL III, et al. Ophthalmology. 2013;120(4):844-851. Agron E, et al. Ophthalmology. 2024;131:1164-1174. Cheung CMG, et al. Lancet. 2017;390(10109):1499-1513.

46

### Role of OCT in Risk Stratification

**Why OCT matters in intermediate AMD**

- Fundus appearance alone underestimates biologic risk
- OCT reveals structural stress before vision loss

**What OCT is used for**

- Identify features associated with higher progression risk
- Help personalize follow-up interval and counseling

**What OCT is not use for**

- Not predict exact timing of progression
- Not to replace clinical judgment

Ferris FL III, et al. Ophthalmology. 2013;120(4):844-851. Nassisi M, et al. Ophthalmology. 2018;125:537-548. Agron E, et al. Ophthalmology. 2024;131:1164-1174.

47

### OCT Biomarkers Associated with Higher Progression Risk

**Hyperreflective Foci (HRF)**

**What they represent**

- Migration of presumed RPE-derived material into the neurosensory retina

**Why they matter**

- Strongly associated with progression to GA and CNV

**Clinical implications**

- Marker of active disease biology
- Justifies closer follow-up and heightened vigilance

**Key takeaway**

- HRF signal increased biologic instability

Nassisi M, et al. Ophthalmology. 2018;125(4):537-548. Christenbury JG, et al. Ophthalmology. 2013;120(5):1038-1045. Folgar FA, et al. Ophthalmology. 2012;119(11):2313-2321.

48

### OCT Biomarkers Associated with Higher Progression Risk

#### Reticular Pseudodrusen (RPD)

**What they are**

- Subretinal drusenoid deposits located **above the RPE**

**Why they matter**

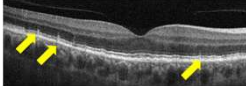
- Associated with faster progression, geographic atrophy, worse functional outcomes

**Detection**

- Best identified with OCT, FAF, near-infrared imaging

**Clinical implications**

- RPD shifts patients into a **higher-risk category**




Spaide RF, et al. *Retina*. 2018;38(11):2107-2117.  
Wu Z, et al. *Ophthalmology*. 2016;123(8):1745-1756.  
Agron, et al. *Ophthalmology*. 2024;131(9):1164-1174.


49

### OCT Biomarkers Associated with Higher Progression Risk

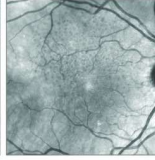
**A** Color fundus photograph



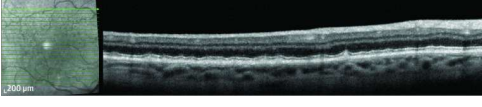
**B** Fundus autofluorescence



**C** Near-infrared reflectance



**D** Spectral-domain optical coherence tomography



**Multimodal Imaging of RPD**

Rougier MB, et al. *JAMA Ophthalmol*. 2020 May;138(5):467-477.

50

### OCT Biomarkers Associated with Higher Progression Risk

#### Drusen Morphology and Volume

**Not all drusen are equal**

- Risk relates to volume, confluence, and internal reflectivity

**Higher-risk features**

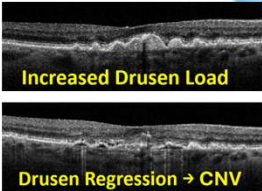
- Large or confluent drusen
- Heterogeneous internal structure

**Clinical implications**

- Suggests more active disease
- Supports shorter monitoring intervals and increased patient education

**Key takeaway**

- Drusen characteristics matter more than size alone



De Sistiemes L, et al. *Ophthalmology*. 2014;121(3):785-795.  
Yehoshua Z, et al. *Ophthalmology*. 2011;118(12):2434-2441.  
Nassisi M, et al. *Ophthalmology*. 2018;125(4):537-548.

51

### OCT Biomarkers Associated with Higher Progression Risk


#### Early Outer Retinal Stress

**What this represents**

- Subtle compromise of photoreceptor integrity
- Structural stress occurring **before** overt atrophy or vision loss

**What to look for on OCT**

- Focal attenuation/disruption of ellipsoid zone
- Subtle irregularity of interdigitation zone



**Why it matters**

- Increased progression risk
- Earlier functional decline under stress

**Clinical implications**

- Reinforces need for closer follow-up
- Helps explain symptoms despite preserved acuity

**Key takeaway**

- Structural stress often precedes measurable functional loss

Schaal KB, et al. *Invest Ophthalmol Vis Sci*. 2015;56(3):1966-1974.  
Oishi A, et al. *Am J Ophthalmol*. 2014;158(4):787-794.  
Wu Z, et al. *Prog Retin Eye Res*. 2014;42:1-24.

52

### OCT Biomarkers: Putting Risk Together

**Key Principle**

- No single OCT finding predicts outcome
- Risk increases as **high-risk factors accumulate**

**Higher-risk OCT features**

- Hyperreflective foci (HRF)
- Reticular pseudodrusen (RPD)
- Large, confluent, or heterogenous drusen
- Early outer retinal stress (ellipsoid zone attenuation)

**What these features indicate**

- Increased biologic activity
- Reduced retinal reserve
- Greater vulnerability to progression

**How this changes management**

- Shorter follow-up intervals
- More focused counseling
- Selective use of advanced tools
- Lower threshold to escalate care

**Key takeaway**

- OCT refines risk - it does not predict outcome

53

### AREDS2: Who Benefits and Why

**What AREDS2 is**

- Evidence-based nutritional supplementation
- Designed to **reduce progression to advanced AMD**, not improve vision

**Who benefits**

- Patients with **intermediate AMD** in one or both eyes
- Patients with **advanced AMD in one eye**

**What AREDS2 does**

- Reduces risk of progression to:
  - Neovascular AMD
  - Visually significant geographic atrophy
- Benefit demonstrated over long-term

**What AREDS2 does not do**

- Does not prevent AMD onset
- Does not benefit patients with early AMD alone
- Does not halt progression entirely

**Clinical role**

- Foundational therapy once intermediate AMD is diagnosed
- Serves as the baseline upon which additional risk-based strategies are layered

**Key takeaway**

- AREDS2 reduces the risk of reaching advanced AMD – it does not treat established disease

Age-related Eye Disease Study 2 Research Group. *JAMA*. 2013;309(19):2005-2015.  
Chew EY, et al. *Ophthalmology*. 2014;121(7):1423-1431.

54

### Pigment Epithelial Detachments (PEDs): Why They Matter

**What PEDs represent**

- Separation of the RPE from Bruch's membrane

**Common PED subtypes**

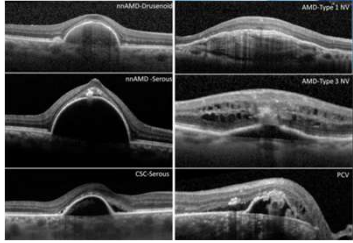
- Drusenoid      - Serous
- Fibrovascular      - Hemorrhagic

**Why PEDs matter**

- Higher progression risk
- Increased risk of developing CNV

**Clinical implications**

- Hemorrhagic PED warrants urgent evaluation
- Lower threshold for OCTA and retina referral



Freund KB, et al. Retina. 2013;33(9):1735-1762.  
Spaide RF, et al. Prog Retin Eye Res. 2020;76:100829.  
Cheung CMG, et al. Lancet. 2018;392(10165):2046-2060.  
Dangsingani KK, et al. Retina. 2016;36(1):1-8.  
Quereques G, et al. Prog Retin Eye Res. 2018;62:1-2

55

### iRORA: Early Atrophic Change on OCT

**What iRORA represents**

- Early, incomplete RPE and outer retinal atrophy
- Structural changes **before clinically obvious GA**

**OCT features**

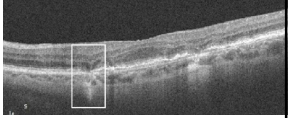
- Subtle RPE attenuation or disruption
- Overlying photoreceptor degeneration
- Increased choroidal signal transmission

**Why iRORA matters**

- Identifies eyes at **higher risk for progression**
- Often precedes development of cRORA (GA)
- Explains symptoms despite preserved acuity

**Clinical implications**

- Shorter follow-up intervals/more detailed counseling



**iRORA is an early warning sign – not yet GA but not benign**

Sadda SR, et al. Ophthalmology. 2018;125(4):537-548.  
Wu Z, et al. Prog Retin Eye Res. 2021;80:100884.

56

### cRORA: Established Atrophy (Geographic Atrophy)

**What cRORA represents**

- Complete RPE and outer retinal atrophy
- OCT-defined correlate of geographic atrophy

**OCT features**

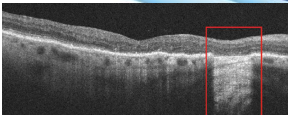
- Complete loss of RPE and photoreceptors
- Marked choroidal hypertransmission
- Corresponds to visible GA on fundus imaging

**Why cRORA matters**

- Represents **irreversible structural damage**
- Associated with permanent functional loss

**Clinical implications**

- Confirms diagnosis of GA
- Guides counseling and referral for GA management



**cRORA confirms established disease – focus shifts to preservation**

Sadda SR, et al. Ophthalmology. 2018;125(4):537-548.  
Guymer RH, et al. Ophthalmology. 2020;127(3):321-329.

57

### AREDS2 and GA: Interpreting the Controversy

**Why this question arises**

- GA reflects **established tissue loss**
- Clinicians question whether supplements influence GA growth once atrophy is present

**Key limitations of GA analyses**

- Secondary or post-hoc endpoints
- Variable GA definitions and imaging methods

**What the data show**

- AREDS and AREDS2 reduce progression to **advanced AMD overall**
- Post-hoc and observational analyses **do not demonstrate meaningful slowing** of GA enlargement once established

**Clinical interpretation**

- No evidence to stop AREDS2 solely due to presence GA

**AREDS2 reduces progression risk in earlier AMD – it does not modify established atrophy**

Chew EY, et al. Ophthalmology. 2014;121(7):1423-1431.  
Keenan TDJ, et al. Ophthalmology. 2021;128(7):1011-1020.  
Hejlic Ophthalmology. Oral micronutrients show no benefit on GA lesion growth. 2025 Dec 22.

58

# Questions?

damon.dierker@esi-in.com

59

### Selective Use of OCT Angiography (OCTA)

**What OCTA adds**


- Visualizes blood flow without dye injection
- Detects vascular changes not seen on structural OCT
- Helps explain symptoms when structure appears stable

**When I consider OCTA**

- Structural OCT shows higher-risk features
  - PRD, HRF, PEDs, or early atrophy
- Symptoms exceed visible structural changes
- Concern for **non-exudative CNV**
- Fellow eye with neovascular AMD

**Clinical role**

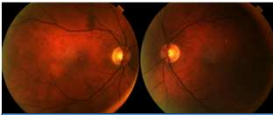
- Refines risk and surveillance strategy
- Does **not** mandate intervention in non-exudative disease



de Carlo TE, et al. Ophthalmology. 2015;122(6):1228-1238.  
Quereques G, et al. Prog Retin Eye Res. 2018;62:1-24.  
Cheung CMG, et al. Lancet. 2017;390(10109):1499-1513.

60

### Case RS 80 yo male – 6-month AMD F/U

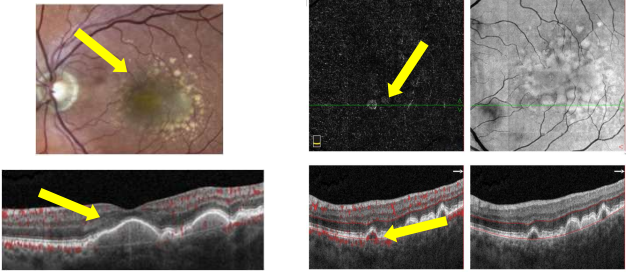


- CC – recent vision changes OU
- POH – intermediate AMD, AREDS2
- PMH – HTN, skin cancer
- BCVA – 20/30 OD, OS
- IOP – 16 OU
- SLEX – PC-IOL w/ clear capsule OU
- Fundus – large coalesced drusen OU

AMD at diagnosis ~ 10 years earlier

61

### Case RS - OCT Angiography



62

### Nonexudative (Subclinical) CNV: Why It Matters

**What this represents**

- Neovascular tissue **without exudation**
- Typically detected only with OCTA

**Why it matters**

- ~15X increased risk of conversion to **exudative disease** compared with eyes without CNV
- Identifies a subgroup requiring closer surveillance

**What it does not mean**

- Not an indication for immediate anti-VEGF therapy
- Not synonymous with wet AMD

**Clinical implications**

- Shorter follow-up intervals
- Lower threshold for urgent evaluation with symptom change
- More explicit counseling

**Non-exudative CNV changes monitoring intensity, not treatment**

de Carlo TE, et al. *Ophthalmology*. 2015;122(6):1228–1238.  
Coscas G, et al. *Ophthalmology*. 2016;123(9):1915–1924.

63

### Genetic Testing in AMD: Selective, Not Universal

**Why genetics are discussed in AMD**

- AMD risk influenced by common genetic variants

**When I consider genetic testing**

- Strong **family history** of advanced AMD
- Patients seeking deeper understanding of personal risk reduction

**Why routine testing is controversial**

- Genetic risk does **not reliably predict individual progression**
- Structural and functional findings may outweigh genotype
- No consensus that results should direct treatment in most patients

**How results are used**

- Inform counseling and expectations
- I may recommend a **zinc-free AREDS2 formulation** if genotype suggests potential zinc sensitivity

**Genetic testing can add context and personalize care**

Chew EY, et al. *Ophthalmology*. 2014;121(7):1423–1431.  
Seddon JM, et al. *JAMA Ophthalmol*. 2016;134(8):845–853.  
Awh CC, et al. *Ophthalmology*. 2013;120(11):2317–2323.

64

### Home Monitoring in Intermediate AMD: Foresee Home

**Why home monitoring matters**

- Conversion to neovascular AMD can occur between scheduled visits
- Earlier detection is associated with **better visual acuity at diagnosis**
- Amsler grid has low sensitivity and inconsistent patient adherence

**What ForeseeHome does**

- Home-based **hyperacuity testing**
- Detects subtle functional change before obvious vision loss
- Automated alerts trigger **expedited in-office evaluation**

**Who benefits most**

- Intermediate AMD with higher-risk features
- Fellow eye with neovascular AMD
- Patients who are cognitively intact and motivated

**Clinical role**

- Does **not replace** scheduled exams
- Used selectively to intensify monitoring, not universally

**Home monitoring improves detection of progression between office visits**

AREDS2-HOME Study Research Group. *Ophthalmology*. 2014;121(2):535–544.  
Ho AC, et al. *Ophthalmology*. 2014;121(2):525–534.

65

### Photobiomodulation (Valeda): Adjunctive Therapy in Intermediate AMD

**What Photobiomodulation (PBM) is**

- Low-level, multiwavelength light therapy
- Targets mitochondrial function and cellular metabolism
- **Valeda Light Delivery System**

**Regulatory status**

- FDA-cleared, not FDA-approved

**Proposed mechanisms**

- Improved mitochondrial efficiency
- Reduced oxidative stress
- Modulation of inflammatory signaling

**What clinical trials suggest**

- **Modest improvement in visual function**
- Structural stability in some intermediate AMD cohorts
- Potential reduction in risk of progression to advanced AMD in selected patients
- Treatment response variable, not universal

**Who I consider for PBM**

- Intermediate AMD with functional complaints
- Motivated patients who understand PBM is **adjunctive**, not definitive therapy

**PBM may offer functional benefit and risk modification in select patients**

Markowitz SN, et al. *Ophthalmol Retina*. 2020;4(2):190–200.  
Ivancic BT, et al. *Clin Ophthalmol*. 2017;11:225–234.  
Eells JT, et al. *Prog Retin Eye Res*. 2016;55:1–28.

66

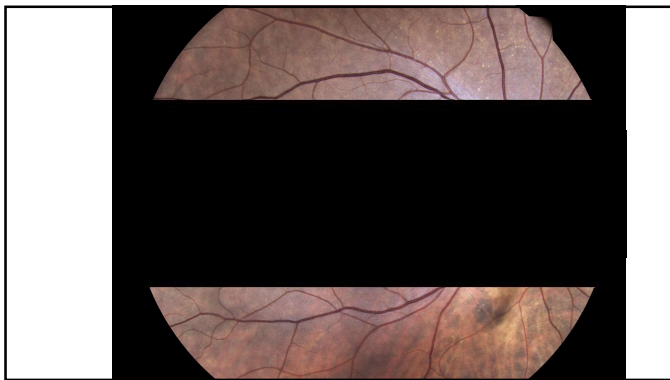
### Intermediate AMD: What I Actually Do in Clinic

<p><b>Typical findings</b></p> <ul style="list-style-type: none"> <li>• Large drusen or extensive medium-sized drusen</li> <li>• Possible pigmentary changes</li> <li>• Visual acuity may remain relatively preserved</li> </ul> <p><b>Imaging</b></p> <ul style="list-style-type: none"> <li>• <b>Color fundus photography</b> <ul style="list-style-type: none"> <li>• Baseline documentation and repeat if significant changes noted</li> </ul> </li> <li>• <b>OCT</b> <ul style="list-style-type: none"> <li>• Identify high-risk features to stratify progression risk</li> </ul> </li> <li>• <b>OCTA</b> <ul style="list-style-type: none"> <li>• In conjunction with OCT for most cases, especially if high-risk features exist</li> </ul> </li> </ul>	<p><b>Monitoring</b></p> <ul style="list-style-type: none"> <li>• In-office follow-up: <b>every 4-12 months</b></li> </ul> <p><b>Patient self-monitoring</b></p> <ul style="list-style-type: none"> <li>• Amsler grid</li> <li>• Consider home monitoring (ForeseeHome)</li> </ul> <p><b>Nutritional strategy</b></p> <ul style="list-style-type: none"> <li>• AREDS2 supplementation</li> <li>• Diet rich in leafy greens and omega-3s</li> <li>• Genetic testing in select patients</li> </ul> <p><b>Adjunctive considerations</b></p> <ul style="list-style-type: none"> <li>• Photobiomodulation (PBM/Valeda) for selected, motivated patients</li> </ul> <p><b>Counseling focus</b></p> <ul style="list-style-type: none"> <li>• Risk is higher but progression is variable</li> <li>• Same risk-reduction strategies as early AMD</li> </ul>
---	--

67

## From Risk Stratification to Referral and Co-Management

68



69

### When to Refer: Suspected or Confirmed CNV

**Referral triggers**

- New **subretinal or intraretinal fluid** on OCT
- New **subretinal or intraretinal hemorrhage**
- Sudden change in vision not explained by dry AMD findings
- OCTA evidence of **active or high-risk neovascularization**

**Why early referral matters**

- Earlier treatment is associated with better visual acuity outcomes

Rosenfeld PJ, et al. N Engl J Med. 2006;355(14):1419-1431.  
Ho AC, et al. Ophthalmology. 2014;121(2):525-534.  
de Carlo TE, et al. Ophthalmology. 2015;122(6):1228-1238.

70

Right / OD      Retina Map, OU Report      Left / OS

**Case**

- 77 yo WM presents for comprehensive exam c/o blurry vision OU
- Has been told that he had "start of AMD" LEE ~1 year ago
- h/o cataract surgery in 2019
- BCVA 20/25 OD, 20/25 OS

71

OD - Central      **Case #1**      OS - Central

2024/01/19 13:39      2024/01/19 13:40

Pixel size: 2.2 mm      Pixel size: 1.7 mm

72

### When to Refer: Geographic Atrophy

#### Referral considerations

- OCT-confirmed **cRORA/geographic atrophy**
- **Typically visual symptoms** (reading difficulty, contrast loss, fixation instability)
- Patient interest in **emerging GA therapies**
- **What I communicate to patient**
- GA therapies **slow progression**, they do not restore vision
- Decisions regarding treatment are individualized and revisited over time
- Ongoing care remains collaborative



Sadda SR, et al. *Ophthalmology*. 2018;125(4):537-548.  
 Guymer RH, et al. *Ophthalmology*. 2020;127(3):321-329.  
 Wu Z, et al. *Prog Retin Eye Res*. 2021;80:100884

73

### Co-Management After Retina Referral

#### Primary eyecare role continues

- Routine ocular health and refractive care
- Management of ocular surface disease and cataract surgery timing
- Ongoing patient education and reassurance

#### Coordination with retina

- Reinforce diagnosis and treatment goals
- Support adherence to injections or monitoring
- Timely exchange of clinical updates

#### Initiate low vision referral when appropriate



Ho AC, et al. *Ophthalmology*. 2014;121(2):525-534.  
 American Academy of Ophthalmology Retina Panel. *Preferred Practice Pattern: Age-Related Macular Degeneration*. 2023.

74

### Key Takeaways: Risk-Based AMD Care

- **AMD is heterogenous** – stage labels alone do not define risk
- **Early AMD** management prioritizes education, lifestyle modification, and appropriate monitoring
- **Intermediate AMD** is the inflection point where management changes
- **AREDS2** reduces progression to advanced AMD when used at the appropriate stage
- **OCT biomarkers** refine risk beyond clinical appearance
- **Adjunctive tools** (OCTA, home monitoring, PBM, genetic testing) are applied selectively, not universally
- **Referral decisions are purposeful**: CNV is time-sensitive, GA is expectation-focused
- **Co-management** preserves continuity of care and improves patient experience

75

## Questions?

damon.dierker@esi-in.com

76

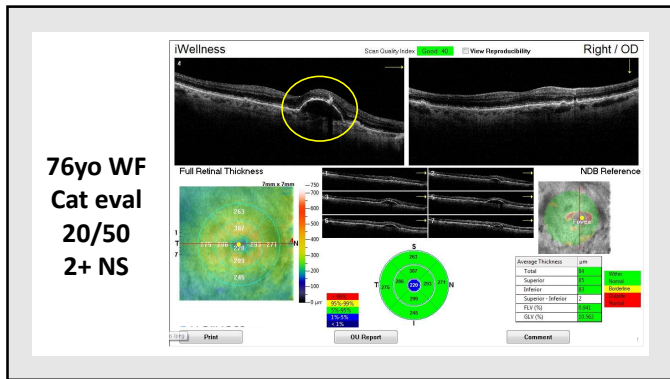
Thank You!

[damon.dierker@esi-in.com](mailto:damon.dierker@esi-in.com)

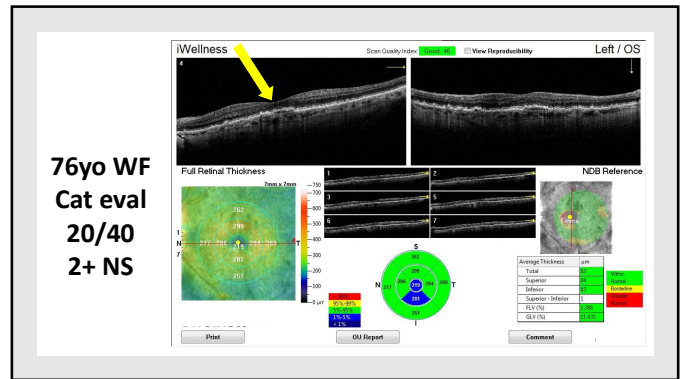
77

Additional Case Example

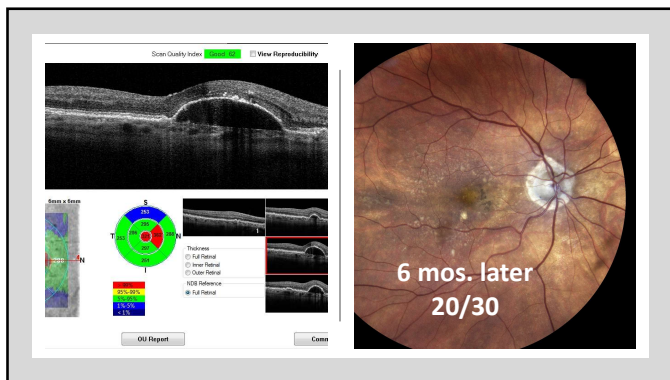
78



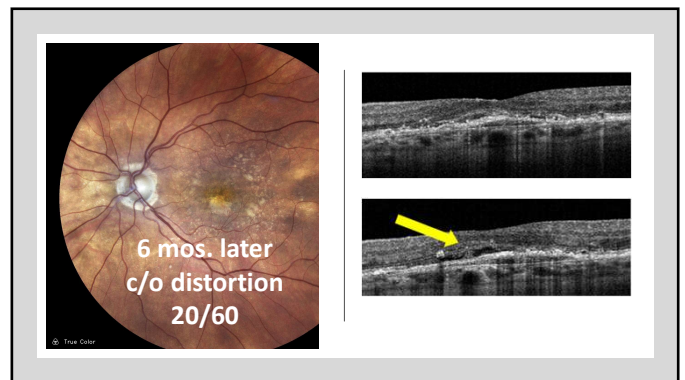
79



80



81



82